

Research Paper

Does an Antibiotic-Loaded Hydrogel Coating Reduce Early Post-Surgical Infection After Joint Arthroplasty?

Carlo Luca Romanò¹✉, Kostantinos Malizos², Nicola Capuano³, Riccardo Mezzoprete⁴, Michele D'Arienzo⁵, Catherine Van Der Straeten^{6,7}, Sara Scarponi¹ and Lorenzo Drago^{8,9}

1. Department of Reconstructive Surgery of Osteo-articular Infections C.R.I.O. Unit, I.R.C.C.S. Galeazzi Orthopaedic Institute, Milano, Italy.
2. Orthopaedic Surgery & Trauma, Medical School, University of Thessaly, Larissa, Greece.
3. Department of Orthopaedics, San Luca Hospital - Vallo della Lucania, Italy.
4. Department of Orthopaedics, San Camillo de Lellis Hospital - Rieti, Italy.
5. Orthopaedic Surgery & Trauma, University Clinic, Palermo, Italy.
6. Department of Orthopaedics, Medical University Ghent, Belgium.
7. MSK Lab, Department of Surgery and Cancer, Imperial College London, London, United Kingdom.
8. Clinical Chemistry and Microbiology Laboratory, I.R.C.C.S. Galeazzi Orthopaedic Institute, Milano, Italy.
9. Laboratory of Medical Technical Sciences, Department of Biochemical Sciences for Health, University of Milano, Italy.

✉ Corresponding author: C.L. Romanò, Department of Reconstructive Surgery of Osteo-articular Infections C.R.I.O. Unit, IRCCS Galeazzi Orthopaedic Institute, Via R. Galeazzi 4 20161 Milan, Italy. Phone: 00390266214907 e-mail: carlo.romano@grupposandonato.it.

© Ivyspring International Publisher. Reproduction is permitted for personal, noncommercial use, provided that the article is in whole, unmodified, and properly cited. See <http://ivyspring.com/terms> for terms and conditions.

Received: 2016.04.27; Accepted: 2016.07.02; Published: 2016.07.19

Abstract

Background: Infection remains among the main reasons for joint prosthesis failure. Preclinical reports have suggested that antibacterial coatings of implants may prevent bacterial adhesion and biofilm formation. This study presents the results of the first clinical trial on an antibiotic-loaded fast-resorbable hydrogel coating (Defensive Antibacterial Coating, DAC®) in patients undergoing hip or knee prosthesis.

Methods: In this multicenter, randomized prospective study, a total of 380 patients, scheduled to undergo primary (n=270) or revision (n=110) total hip (N=298) or knee (N=82) joint replacement with a cementless or a hybrid implant, were randomly assigned, in six European orthopedic centers, to receive an implant either with the antibiotic-loaded DAC coating (treatment group) or without coating (control group). Pre- and postoperative assessment of clinical scores, wound healing, laboratory tests, and x-ray exams were performed at fixed time intervals.

Results: Overall, 373 patients were available at a mean follow-up of 14.5 ± 5.5 months (range 6 to 24). On average, wound healing, laboratory and radiographic findings showed no significant difference between the two groups. Eleven early surgical site infections were observed in the control group and only one in the treatment group (6% vs. 0.6%; p=0.003). No local or systemic side effects related to the DAC hydrogel coating were observed, and no detectable interference with implant osteointegration was noted.

Conclusions: The use of a fast-resorbable, antibiotic-loaded hydrogel implant coating can reduce the rate of early surgical site infections, without any detectable adverse events or side effects after hip or knee joint replacement with a cementless or hybrid implant.

Key words: joint prosthesis, infection

Introduction

An estimated 157,500 surgical site infections (SSIs) associated with inpatient surgeries occurred in the United States in 2011 according to a prevalence survey by the U.S. Centers for Disease Control and Prevention (CDC) [1]. In spite of improvements in operating room practices, sterilization methods,

physical barriers, surgical techniques, and routine systemic antimicrobial prophylaxis [2-5], SSIs remain the most common healthcare-associated infection [6], with an incidence of up to 2.5% after primary hip and knee arthroplasty and 10% following revision surgery [7] and an increased relative risk of infection in

high-risk patients [8-11]. These figures could be underestimated, however, owing to the increasing occurrence of multidrug-resistant pathogens [12, 13].

Periprosthetic infection often necessitates implant removal and is responsible for a disproportionate burden of morbidity and mortality [14] and elevated economic and social costs [15, 16].

Recognizing these problems, researchers from Stanford University suggested that “coatings of devices would be most useful in the prevention and treatment of implant-associated infection” [17] and a similar recommendation was delivered at a consensus meeting on periprosthetic joint infections [18]. However, developing new antibacterial implant coatings appears extremely challenging [19, 20].

Biocompatible hydrogels are able to deliver pharmacological agents locally and may be designed to meet the desired elution pattern [21]. Recently, a fast-resorbable hydrogel coating that works as a physical barrier to bacterial adhesion and that can be intra-operatively loaded with various antibacterials has been developed [22]. Based on the observation that bacterial colonization, from microbial adhesion to an established mature biofilm layer, only takes few hours [23] and given the known efficacy of short-term systemic antibiotic prophylaxis [24], a fast-resorbable antibacterial coating may provide “short-term local protection”, while limiting possible long-term unwanted side effects [25]. This novel hydrogel coating (Defensive Antibacterial Coating [DAC®], Novagenit Srl, Mezzolombardo, Italy), composed of

covalently linked hyaluronan and poly-D,L-lactide, is designed to undergo complete hydrolytic degradation within 72 hours, during which it completely releases a variety of antibacterials at concentrations ranging from 2% to 10%. The hydrogel showed synergistic activity with various antibiotics and antibiofilm agents *in vitro* [26]. Also, it has been proven safe and effective *in vivo* in a rabbit model of highly contaminated implant both with [27] and without systemic antibiotic prophylaxis [28].

Following a brief previous report [29], we here present the results of a multicenter European trial on this novel technology applied to total hip and knee joint prosthesis.

Patients and methods

From November 2013 to June 2015, 380 patients were included in this prospective, observational multicenter study (Fig. 1). The study protocol was approved by the local Ethical Committees of the six participating centers. All patients gave their informed consent to the procedure. The study was performed within the 7th European Framework Programme (project # 277988) and funded by the European Commission and the participating partners (clinical institutions and the following private companies: Novagenit SRL, Mezzolombardo, Italy, acting as project leader; AdlerOrtho SRL, Bologna, Italy; Arcos SARL, Brignoles, France; Belgafix SPRL, Drogenbos, Belgium).

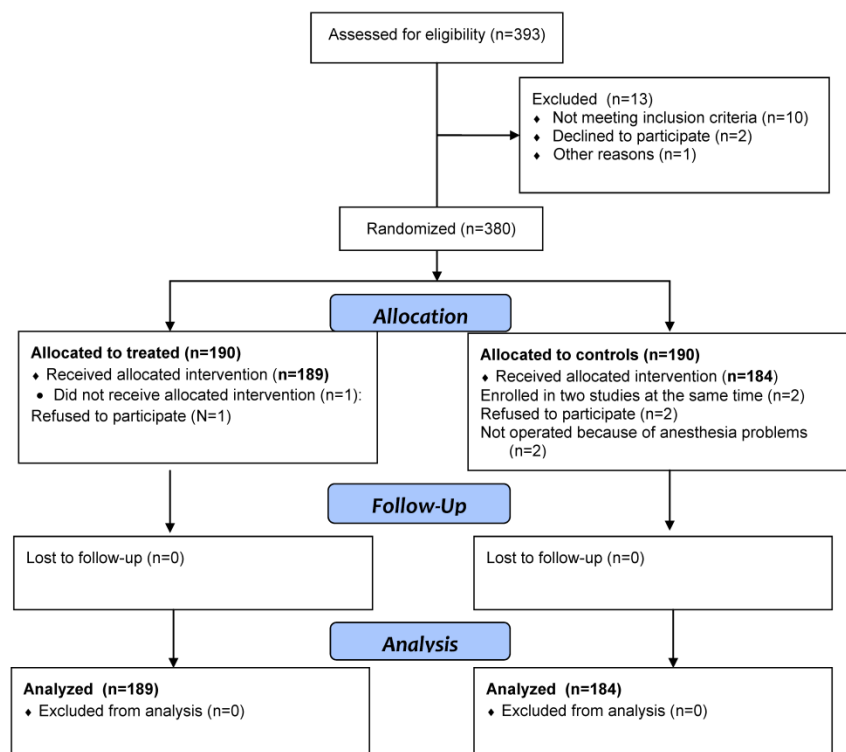


Figure 1. Consort flow diagram of patient enrollment.

Treatment assignment at each study center was generated by an electronic system; patients were assigned to receive an implant either with the antibiotic-loaded DAC (DAC®) coating (treatment group) or without the coating (control group).

Inclusion criteria were: the need for a cementless or hybrid (partially cemented) total hip or knee prosthesis and age > 18 years. Exclusion criteria were: pregnancy, breast-feeding or planning to become pregnant during the study period, the presence of an active infection at the site of surgery, severe malignancies with a life expectancy of less than 3 months, previous diagnosis of immune depression or immunosuppressive treatment for organ transplantation, known allergy to the antibiotics or the DAC hydrogel constituents, unwillingness or inability to present for follow-up examinations or refusal to sign the informed consent documents or inability to do so.

Surgical treatment and DAC preparation

After routine pre-operative workup, all patients underwent total joint replacement according to the current practice of each participating center. The surgical approach and type of implant was left to the surgeon's discretion; similarly, systemic antibiotic prophylaxis was given according to each center's routine protocol [30]. All patients received low-molecular-weight heparin for deep vein thrombosis prophylaxis or oral anticoagulants for 4 to 6 weeks postoperatively. Patients undergoing hip arthroplasty received prophylaxis with indomethacin or celecoxib for 2 weeks after surgery to prevent heterotopic bone formation.

Reconstitution of the DAC® hydrogel was performed according to the manufacturer's instructions. Briefly, a prefilled syringe, containing 300 mg sterile DAC powder (Fig. 2), was filled at surgery with a solution of 5 mL sterile water for injection and the desired antibiotic to obtain in approximately 3 to 5 minutes the antibiotic-loaded hydrogel at a DAC concentration of 6% (w/v) and an antibiotic concentration ranging from 20 mg/mL to 50 mg/mL, depending on the surgeon's choice. The surgeons could choose the antibiotic from among a list of antibacterials previously tested as being compatible with the hydrogel (Novagenit SRL, data on file). A few minutes after reconstitution, the hydrogel was directly spread onto the implant, which was then inserted into the body in the usual way (Figs. 3 and 4).



Figure 2. The “Defensive Antibacterial Coating ([DAC®] Novagenit Srl, Mezzolombardo, Italy) is a fast-resorbable hydrogel coating composed of covalently linked hyaluronan and poly-D,L-lactide. It is supplied in a prefilled syringe as a powder that is reconstituted at the time of surgery with a solution composed of sterile water for injection and antibiotic(s).

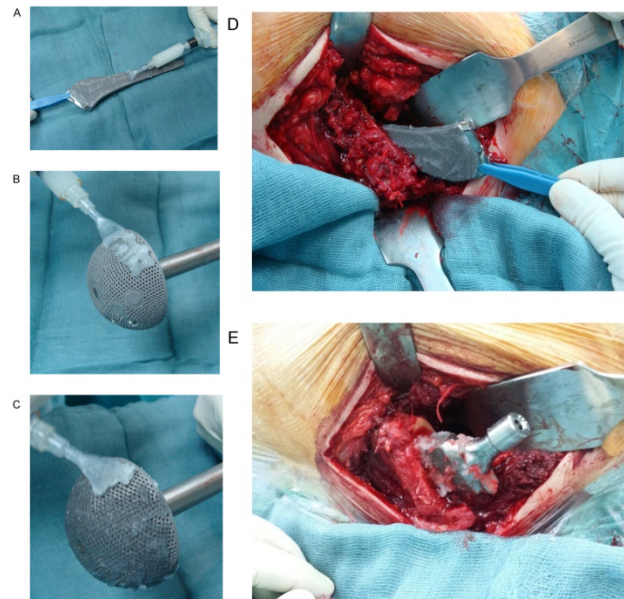


Figure 3. The antibiotic-loaded hydrogel coating is spread onto a stem (A) and an acetabular cup (B and C), which may then be applied directly on the bone in the usual way (D). More hydrogel can be spread on the extra-medullary part of the implant (E).

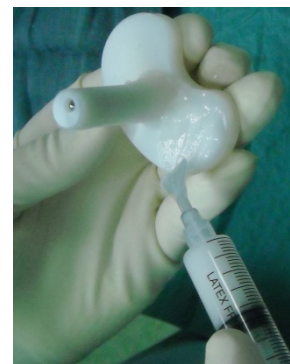

Figure 4. The hydrogel can be applied to modular parts, as shown here on the polyethylene tibial insert of a revision knee prosthesis, to provide a complete surface protection.

Assessments

The main outcome was the absence of adverse events and side effects related to the hydrogel coating, as assessed by clinical, laboratory and radiographic examinations. Another targeted main outcome was a reduction in SSIs, as defined below, in the treatment group as compared with the controls. Secondary outcomes were a reduction in delayed wound healing in the treatment versus the control group.

All patients underwent pre-operative clinical, radiographic, and laboratory tests examinations. Host type was classified according to McPherson et al. [31]. Wound healing was assessed at postoperative days 7 and 14 using the ASEPSIS scoring method [32]; serum laboratory tests, x-ray and clinical evaluations were scheduled at 6 ± 4 weeks, 3 months ± 4 weeks, 6, 12, 18, and 24 months ± 8 weeks postoperatively. Clinical evaluation was performed using the SF-12 Health Survey score and the Harris Hip or the Knee Society Scores as appropriate; any signs of early SSI, including pain, redness, warmth, swelling, draining wound, fistulas, etc., according to the CDC Procedure-associated Module SSI (<http://www.cdc.gov/nhsn/PDFs/pscManual/9pscSSICurrent.pdf>) were also recorded.

SSIs were defined as the presence of positive local clinical signs of acute inflammation and/or a draining sinus requiring further surgery, including early debridement or implant removal and/or unplanned antibiotic treatment with or without a positive cultural examination. Delayed wound healing was defined as an incomplete healing of the wound at 4 weeks after surgery, including the presence of wound dehiscence, necrosis or serum leakage, that may need further medication, but that did not require any additional surgical treatment. Serious adverse events and complications or side effects were also recorded whenever present at follow-up. Radiographic examination, including evaluation of osteolysis or progressive (> 2 mm) radiolucent lines around the implant or signs of implant loosening or sinking, was performed by an independent radiologist unaware of assignment to DAC treatment.

Statistical analysis

Descriptive statistics were used to summarize the data. Categorical data were analyzed using Fisher's exact test; continuous data were compared using Student's t test (<http://graphpad.com/>). P-values of less than 0.05 were considered statistically significant. Sample size was calculated assuming an overall SSI incidence of 1% in the treatment group and of 6% in the control group and a 10% dropout rate

(alpha error: 0.05, power 0.80; cf. <https://www.stat.ubc.ca/~rollin/stats/ssize/b2.html>).

Results

Seven patients dropped out of the study after randomization (Fig. 1); a total of 373 patients (189 treated and 184 controls) were available at an average follow-up of 14.5 ± 5.5 months (range 6 to 24) (Table 1). There were no significant differences in age, sex, site of surgery, and host type between the two groups. Peri-operative data (Table 2) showed that the majority of the patients required a primary hip joint replacement and approximately 30% in both groups underwent revision surgery. Revision surgery was performed as a part of a two-stage procedure for infection in 48 (92.3%) patients in the control group and in 51 (94.4%) patients in the treatment group. Primary hip and knee replacement was performed at five centers; revision procedures were performed at three centers. Cefazolin was the most often used antibiotic for short-term prophylaxis in both groups; combined systemic short-term prophylaxis was administered in approximately half of the patients (Table 2).

Table 1. Patient demographics and pre-operative data. Host type is defined according to McPherson's classification.

	Controls	%	Treated	%	P	
Male	74	40.2	81	42.9	0.67	
Female	110	59.8	108	57.1		
Total	184	100.0	189	100.0		
Age (years)	Mean ± SD	71 ± 10.6	69 ± 12.6		0.09	
	Min - Max	36 - 96	39 - 88			
Host Type	A	43	23.4	45	23.8	1.00
	B	127	69.0	124	65.6	
	C	14	7.6	20	10.6	

Table 2. Peri-operative data.

	Controls	%	Treated	%	P	
Joint	Hip	141	76.6	153	80.9	0.31
	Knee	43	23.4	36	19.0	
Type of surgery	Primary	132	71.7	135	71.8	1
	Revision	52	28.3	54	28.2	
Systemic prophylaxis	Cefazolin	76	41.3	69	48.2	
	Cefazolin + Glycopeptides	10	5.4	29	20.3	
	Cefazolin + Vancomycin	51	27.7	46	38.3	
	Vancomycin + Meropenem	47	25.5	45	31.5	
DAC volume (mL)	Mean ± SD	N/A	8.3 ± 2.7			
	Min - Max	N/A	5 - 10			
DAC + vancomycin		N/A	100	52.9		
5%						
DAC + gentamicin		N/A	70	37.0		
3.2%						
DAC + vancomycin		N/A	15	7.9		
2% + meropenem 2%						
Other associations			4	2.1		

On average, a volume of 8.3 mL DAC hydrogel was used to coat an implant. The most often used antibiotics were vancomycin and gentamicin at a concentration of 5% and 3.2%, respectively. Fifteen patients received an implant with a combined vancomycin and meropenem antibiotic coating; 4 patients received an implant coated with teicoplanin 5% or ceftazidime 5% or amphotericin B 5%, all in a second-stage procedure for previous infection (microorganism-targeted local antibiotic coating).

There was no difference in time to early wound healing between the two groups: the mean ASEPSIS score at 7 and 14 days was 2.6 ± 4.9 and 2.1 ± 6.1 in the control group and 1.9 ± 4.2 and 1.9 ± 5.3 in the treatment group, respectively. Unplanned antibiotic treatment during hospital stay, for reasons other than SSI (mainly urinary or respiratory tract infections), was recorded in 8 (4.3%) patients in the control group and in 9 (4.7%) in the treatment group.

There were no significant differences in serum laboratory values and average clinical scores between the two groups at the first follow-up visit (Tables 3 and 4). At the 6-month control visit, C-reactive protein values exceeded 10 mg/L in 12 (6.5%) patients in the control group and in 5 (2.6%) patients in the treatment group ($P=0.08$). Delayed wound healing was recorded in 7 (3.8%) patients in the control group and in 2 (1.2%) in the treatment group ($P=0.1$).

Four SSIs were reported in the control group of patients undergoing primary joint arthroplasty ($N=132$; 3%) and one SSI in the treatment group ($N=135$; 0.7%); the mean infection rate after primary joint arthroplasty in the control group was 0% in two centers and 2.5%, 3.7%, and 4.5% in the three other centers, respectively. Seven post-surgical infections were observed in the controls undergoing a revision procedure ($N=52$; 13.4%) and none in the treatment group ($N=54$). The mean infection rate after revision joint arthroplasty in the control group was 10.3%, 16.7%, and 17.6% in three centers. Overall, 11 SSIs were reported in the control group and only one in the treatment group (6.0% vs. 0.6%; $P=0.003$). When only patients with a minimum follow-up of 12 months were included in the analysis, the overall incidence of post-surgical infection was 6.4% in the controls (8/125) and 0% (0/126) in the treatment arm ($P=0.003$).

Table 5 presents details on septic complications, treatment and outcome. The complications included: hip prosthesis dislocation ($n=1$) treated with modular parts exchange, knee stiffness ($n=2$), and deep vein thrombosis after total knee replacement ($n=2$) in the control group; hip revision prosthesis dislocation ($n=1$) treated conservatively, deep vein thrombosis after hip revision surgery ($n=2$), and stiff knee after

revision ($n=1$) in the treatment group. No allergic or skin reactions or adverse events related to the hydrogel coating were reported in either group.

Radiographic examination revealed no signs of focal osteolysis around the implant in either group; progressive (> 2 mm) radiolucent lines around the implant were observed in 3 patients in the treatment group and in 7 patients in the control group; no signs of implant loosening or sinking were reported in either group and no Brooker 3 or 4 heterotopic ossifications were observed. (Fig. 5).

Table 3. Serum laboratory values at 6 months after index surgery.

	Controls	Treated	
	Mean \pm SD	Mean \pm SD	P
Erythrocyte Sedimentation Rate (mm/h)	28.0 ± 9.7	26.8 ± 21.9	0.49
C-reactive Protein (mg/L)	10 ± 17	7.5 ± 12	0.1
Hemoglobin (g/100 mL)	13.0 ± 1.1	13.2 ± 1.4	0.11
White Blood Cells (cells/mL)	7023 ± 1057	6854 ± 1824	0.27
Polymorphonuclear leukocytes (%)	56.9 ± 6.6	57.5 ± 9.2	0.47
Creatinine (mg/dL)	0.8 ± 0.1	0.8 ± 0.2	1
SGOT (U/L)	19.8 ± 9.8	18.8 ± 5.7	0.28
SGPT (U/L)	18.5 ± 14	18.1 ± 8.7	0.74
GAMMA-GT (U/L)	33.5 ± 46.1	27.4 ± 34.1	0.15

Table 4. Postoperative data at the latest follow-up.

		Controls	%	Treated	%	P
Follow-up (months)	Mean \pm SD	13.9 ± 2.7		13.3 ± 5.0		0.6
	Min - Max	8 - 24		6 - 24		
SF-12 - Physical score	Mean \pm SD	45 ± 14.7		47.7 ± 15.5		0.11
SF-12 - Mental score	Mean \pm SD	49.7 ± 15.9		52.2 ± 15.5		0.12
SF-12 - Total score	Mean \pm SD	94.7 ± 18.3		99.9 ± 18.4		0.006
Harris Hip Score	Mean \pm SD	83.4 ± 16.7		86.4 ± 16		0.08
Knee Society Score	Mean \pm SD	79.4 ± 20.5		75.8 ± 21.7		0.1
Complications	Surgical site infection	11	6.0	1	0.6	0.003
	Delayed wound healing	7	3.8	2	1.2	0.1
	Other complications	5	2.7	4	2.1	0.7

Discussion

This is the first clinical trial to report on the safety and efficacy of a fast-resorbable antibiotic-loaded hydrogel coating for total joint replacement. Consistent with previous *in vivo* studies [26, 28], our data show that use of the hydrogel coating is clinically safe and devoid of any detectable local or systemic side effects in the short-term follow-up. The biocompatibility of the hydrogel basic components and the short time to resorption [19, 22] make the possible occurrence of delayed side effects quite unlikely. Also, our results showed a ten-fold reduction in the occurrence of early SSIs in the treated

patients as compared with the controls. This confirms prior *in vivo* studies [26, 28] and is the first demonstration of clinical efficacy that short-term local

prophylaxis may reduce post-surgical septic complications after joint replacement.

Table 5. Demographic and clinical characteristics of patients receiving total hip or knee replacement.

Patient initials	Age	Sex	Host type	Relevant co-morbidities	Pre-operative diagnosis	Type of implant	Onset of infection (months from surgery)	Cultural examination	Other complications	Treatment	Final outcome
Control patients											
SS	72	M	C	Previous PJI and multiple surgeries; Diabetes; Depression	2 nd stage hip revision	Cementless modular revision hip prosthesis	2	MRSA	Delayed wound healing	Prolonged antibiotic treatment	Suppressive antibiotic treatment
RF	76	M	B	Diabetes	Knee osteoarthritis	Cementless knee prosthesis	2	MRSE		Debridement and irrigation	No local signs of infection, but painful
CF	78	F	B	Previous PJI	2 nd stage hip revision	Cementless modular revision hip prosthesis	1	MSSA	Delayed wound healing	Debridement and irrigation	No local signs of infection
DF	60	M	B	Previous PJI	2 nd stage hip revision	Cementless modular revision hip prosthesis	3	MRSA		Prosthesis removal and spacer implant	Awaiting further surgery
SE	81	F	A		Hip osteoarthritis	Cementless hip prosthesis	4	MSSE		Two-stage revision surgery	No local signs of infection
VPM	61	M	B	Diabetes; Nicotine abuse	Knee osteoarthritis	Cementless knee prosthesis	6	MSSE		Prosthesis removal and spacer implant	Awaiting further surgery
MA	82	M	B	Previous PJI; Old age	2 nd stage knee revision	Hybrid total knee modular implant	< 1	MRSA		Debridement and irrigation	No further infection recurrence
GA	74	F	C	Previous PJI and multiple surgeries; Diabetes	2 nd stage knee revision	Hybrid total knee modular implant	5	<i>E. coli</i> ; MRSA	Delayed wound healing	Knee arthrodesis	No local signs of infection
PA	73	M	B	Previous PJI	2 nd stage knee revision	Hybrid total knee modular implant	6	<i>S. epidermidis</i>	Skin necrosis	Prosthesis removal and spacer implant	Awaiting further surgery
MA	63	F	B	Diabetes; Previous surgeries	Post-traumatic knee osteoarthritis	Hybrid total knee modular implant	4	MRSE		Two-stage reimplantation	No further infection recurrence
BA	62	F	C	Previous PJI; Rheumatoid arthritis; Corticosteroid therapy	2 nd stage knee revision	Hybrid total knee modular implant	2	MRSA		Debridement and irrigation	Suppressive antibiotic therapy
Treated patients											
VN	71	F	B	Diabetes; BMI > 40	Hip osteoarthritis	Cementless hip prosthesis	< 1	Negative cultures	Delayed wound healing	Debridement and irrigation	No further infection recurrence

PJI denotes prosthetic joint infection; MRSA methicillin-resistant *Staphylococcus aureus*; MSSE methicillin-sensitive *Staphylococcus epidermidis*; MRSE methicillin-resistant *Staphylococcus epidermidis*; BMI body-weight index (weight in kg divided by height in meters squared)

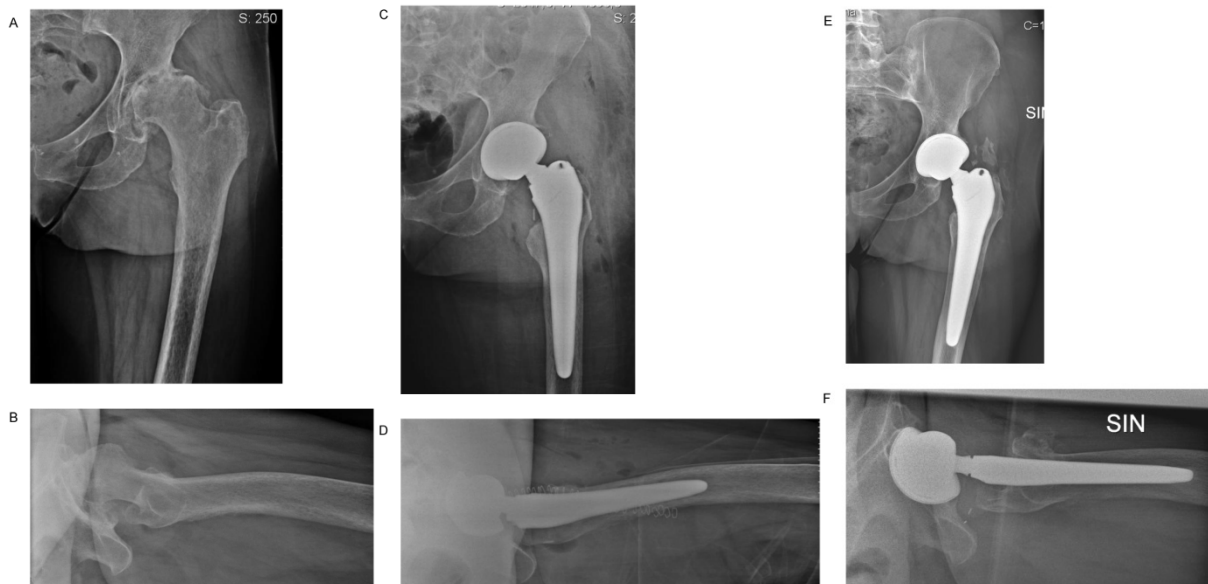

Figure 5. Female, 56 years old. Severe rheumatoid arthritis. Cementless total hip arthroplasty, coated with vancomycin 5% loaded DAC hydrogel. A and B. Pre-operative x-ray. Immediate (C and D) and (E and F) postoperative radiographic images at 18 months showing complete implant osteointegration at follow-up.

Although still observed after primary joint replacement, the protective effect was much more evident in the patients undergoing revision surgery. It should be noted that approximately 75% of the patients in both groups were type B or C hosts and that the majority of revision surgeries were performed in previous infection.

Historically, local administration of antibiotics has attracted much attention in orthopedics. Buchholz et al. were the first to popularize the incorporation of antibiotics into polymethylmethacrylate (PMMA) bone cement for local antibiotic prophylaxis in cemented total joint arthroplasty [33]. Clinical studies have shown that antibiotic-loaded bone cement can decrease deep infection rates of cemented total hip arthroplasties and revision rates due to suspected "aseptic" loosening when combined with systemic antibiotic administration [34]. This solution has proven both effective and economically sound, especially in high-risk patients [35, 36]. However, because PMMA was not designed as a local delivery carrier of antibiotics it may have some limitations. Antibiotic-loaded PMMA may not prevent biofilm formation and may be associated with the development of antibiotic-resistant "small-colony variants" [37, 38]. Furthermore, the increasing use of cementless implants worldwide, especially at the hip, make this option possible for only a limited number of patients.

Antibacterial coatings have been shown to be clinically effective [19, 39]. Silver coating is probably the most extensively studied [40], though concerns have been raised about the possible toxicity of silver ions [41]. To overcome this problem, research efforts have recently focused on new silver coating technologies [42, 43]. However, despite the demonstrated clinical efficacy in two comparative studies on a small series of patients [44, 45], the routine use of silver-coated implants remains rather limited. Excellent clinical efficacy was recently demonstrated for iodine coating of titanium alloys in a continuous, non-comparative series of patients undergoing joint replacement [46]. However, the unknown long-term, questionable large-scale applicability, and the complex regulatory pathway still limit this technology. Biodegradable polymers and sol-gel coatings have been shown to provide controlled antibiotic release on titanium [47, 48] or hydroxyapatite implants [49], offering ease of use, versatility, and possible large-scale application. In the present application, the anti-adhesive ability of the DAC hydrogel has been coupled to local antibiotic administration, to reduce the chance for planktonic bacteria to colonize the implant.

This study has some limitations. First, the follow-up period was relatively short. Although the minimum of 6 months monitoring appears adequate to detect early post-surgical septic complications, as defined by Infectious Diseases Society of America (IDSA) guidelines [50], longer follow-up periods are necessary to further investigate delayed or late periprosthetic infections. In this regard, it should also be noted that the analysis of the patient subgroups observed for a minimum follow-up of 12 months did confirm the difference between the treatment and the control groups. Second, the study design deliberately left the choice of systemic antibiotic used for prophylaxis and the one added to the hydrogel locally at the discretion of each study center. Indeed, there is no scientific evidence showing the superiority of one antibiotic prophylaxis over another after joint prosthesis [51]. Other limitations are the exclusion of infected joint prostheses and other potentially challenging clinical situations in which an antibacterial coating could be useful. This is will be addressed in separate ongoing studies.

Competing Interests

The authors have declared that no competing interest exists.

References

- Magill S.S., et al. Multistate point-prevalence survey of health care-associated infections. *New England J of Medicine*, 2014;370(13): 1198-1208.
- An, Y.H.; Friedman, R.J. Prevention of sepsis in total joint arthroplasty. *J Hosp Infect* 1996, 33: 93-108.
- Humphreys, H. Surgical site infection, ultraclean ventilated operating theatres and prosthetic joint surgery: Where now? *J Hosp Infect* 2012, 81:71-72.
- Jansen E, Furnes O, Engesaeter LB, Kontinen YT, Odgaard A, Stefansdottir A, et al. Prevention of deep infection in joint replacement surgery. *Acta Orthop* 2010;81:660e6.
- Illingworth K.D., et al. How to minimize infection and thereby maximize patient outcomes in total joint arthroplasty: a multicenter approach: AAOS exhibit selection. *J Bone Jt Surg Am*. 2013, 95:e50.
- Magill S.S., et al. Prevalence of healthcare-associated infections in acute care hospitals in Jacksonville, Florida. *Infection Control Hospital Epidemiology*, 2012;33(3): 283-91.
- Lentino J.R. Prosthetic joint infections: Bane of orthopedists, challenge for infectious disease specialists. *Clin. Infect. Dis*. 2003, 36: 1157-1161.
- Illingworth K.D., et al. How to minimize infection and thereby maximize patient outcomes in total joint arthroplasty: a multicenter approach: AAOS exhibit selection. *J. Bone Jt. Surg. Am*. 2013, 95: e50.
- Pruzansky JS, Bronson MJ, Grelsamer RP, Strauss E, Moucha CS. Prevalence of modifiable surgical site infection risk factors in hip and knee joint arthroplasty patients at an urban academic hospital. *J. Arthroplast*. 2014;29:272-276.
- Berbari EF, Osmon DR, Lahr B, Eckel-Passow JE, Tsaras G, Hanssen AD, Mabry T, Steckelberg J, Thompson R. The Mayo prosthetic joint infection risk score: Implication for surgical site infection reporting and risk stratification. *Infect. Control Hosp. Epidemiol*. 2012;33:774-781
- Aggarwal V.K., et al. Mitigation and education. *J. Arthroplast*. 2014, 29: 19-25.
- Dale, H.; Hallan, G.; Hallan, G.; Espehaug, B.; Havelin, L.L.; Engesaeter, L.B. Increasing risk of revision due to deep infection after hip arthroplasty. *Acta Orthop*. 2009, 80: 639-645.
- Aggarwal VK, Bakhshi H, Ecker NU, Parvizi J, Gehrke T, Kendoff D. Organism profile in periprosthetic joint infection: Pathogens differ at two arthroplasty infection referral centers in Europe and in the United States. *J. Knee Surg*. 2014, 10, doi:10.1055/s-0033-1364102.
- Zmistowski B, Karam JA, Durinka JB, Casper DS, Parvizi J. Periprosthetic joint infection increases the risk of one-year mortality. *J. Bone Jt. Surg. Am*. 2013;95:2177-2184
- Kurtz, SM, Lau E, Watson H, Schmier JK, Parvizi J. Economic burden of periprosthetic joint infection in the United States. *J. Arthroplast*. 2012;27:61-65.
- Poultides LA, Liaropoulos LL, Malizos KN. The socioeconomic impact of musculoskeletal infections. *J Bone Joint Surg Am* 2010; 92:e13.

17. Goodman SB, Yao Z, Keeney M, Yang F. The future of biologic coatings for orthopaedic implants. *Biomaterials*. 2013; 34(13): 3174–3183.
18. Cats-Baril W, Gehrke T, Huff K, Kendoff D, Maltenfort M, Parvizi J. International consensus on periprosthetic joint infection: Description of the consensus process. *Clin. Orthop. Relat. Res.* 2013;471: 4065–4075.
19. Romanò CL, Scarponi S, Gallazzi E, Romanò D, Drago L. Antibacterial coating of implants in orthopaedics and trauma: a classification proposal in an evolving panorama. *J Orthop Surg Res.* 2015; 10: 157.
20. Romanò CL, Logoluso N, Drago L. Antibiofilm strategies in orthopedics: where are we? In: *Peri-Operative Medical Management for Total Joint Arthroplasty*. Springer. 2014: 269-286.
21. Overstreet D, McLaren A, Calara F, Vernon B, McLemore R. Local gentamicin delivery from resorbable viscous hydrogels is therapeutically effective. *Clin Orthop Relat Res.* 2015 Jan;473(1):337-47.
22. Pitarresi G, Palumbo FS, Calascibetta F, Fiorica C, Di Stefano M, Giammona G. Medicated hydrogels of hyaluronic acid derivatives for use in orthopedic field. *Int J Pharm.* 2013 Jun 5;449(1-2):84-94.
23. Holá V, Růžička F, Votava M. The dynamics of staphylococcus epidermis biofilm formation in relation to nutrition, temperature, and time. *Scripta Medica* 2006; 79:169-174
24. Heydemann JS, Nelson CL. Short-term preventive antibiotics. *Clin Orthop Relat Res.* 1986 Apr;(205):184-7.
25. Antoci Jr V, Adams CS, Hickok NJ, Shapiro IM, Parvizi J. Antibiotics for local delivery systems cause skeletal cell toxicity in vitro. *Clin Orthop Relat Res* 2007;462:200-6.
26. Drago L, Boot W, Dimas K, Malizos K, Hänsch GM, Stuyck J, Gawlitta D, Romanò CL. Does implant coating with antibacterial-loaded hydrogel reduce bacterial colonization and biofilm formation in vitro? *Clin Orthop Relat Res.* 2014 Nov;472(11):3311-23.
27. Giavaresi G, Meani E, Sartori M, Ferrari A, Bellini D, Sacchetta AC, Meraner J, Sambri A, Vocale C, Sambri V, Fini M, Romanò CL. Efficacy of antibacterial-loaded coating in an in vivo model of acutely highly contaminated implant. *Int Orthop.* 2014 Jul;38(7):1505-12.
28. Boot W, Vogely HCh, Nikkels PGJ, Pouran B, van Rijen M, Dhert WJA, Gawlitta D. Local prophylaxis of implant-related infections using a hydrogel as carrier. *European Cells and Materials* 2015;30(2):19.
29. Malizos K, Scarponi S, Simon K, Blauth M, Romanò C. Clinical results of an anti-bacterial hydrogel coating of implants: a multi-centre, prospective, comparative study. *Bone Joint J* 2015;97:138.
30. Slobogean GP, Kennedy SA, Davidson D, O'Brien PJ. Single- versus multiple-dose antibiotic prophylaxis in the surgical treatment of closed fractures: a meta-analysis. *J Orthop Trauma.* 2008 Apr;22(4):264-9.
31. McPherson EJ, Woodson C, Holtom P, Roidis N, Shufelt C, Patzakis M. Periprosthetic total hip infection. Outcomes using a staging system. *Clin Orthop Relat Res.* 2002;403:8–15.
32. Wilson AP, Treasure T, Sturridge MF, et al. A scoring method (ASEPSIS) for postoperative wound infections for use in clinical trials of antibiotic prophylaxis. *Lancet.* 1986;1:311Y313.
33. Buchholz HW, Engelbrecht H. Depot effects of various antibiotics mixed with Palacos resins. *Der Chirurg; Zeitschrift für alle Gebiete der operativen Medizin* 1970;41:511e5.
34. Engesaeter LB, Lie SA, Espehaug B, Furnes O, Vollset SE, Havelin LI. Antibiotic prophylaxis in total hip arthroplasty: effects of antibiotic prophylaxis systemically and in bone cement on the revision rate of 22,170 primary hip replacements followed 0-14 years in the Norwegian Arthroplasty Register. *Acta Orthop Scand* 2003;74:644e51.
35. Gutowski CJ, Zmistowski BM, Clyde CT, Parvizi J. The economics of using prophylactic antibiotic-loaded bone cement in total knee replacement. *Bone Joint J.* 2014 Jan;96(1):65-9.
36. Dunbar MJ. Antibiotic bone cements: their use in routine primary total joint arthroplasty is justified. *Orthopedics.* 2009 Sep;32(9).
37. van de Belt H, Neut D, Schenk W, van Horn JR, van Der Mei HC, Busscher HJ. Staphylococcus aureus biofilm formation on different gentamicin-loaded polymethylmethacrylate bone cements. *Biomaterials.* 2001 Jun;22(12):1607-11.
38. Neut D, Hendriks JG, van Horn JR, van der Mei HC, Busscher HJ. Pseudomonas aeruginosa biofilm formation and slime excretion on antibiotic-loaded bone cement. *Acta Orthop.* 2005 Feb;76(1):109-14.
39. Gallo J, Holinka M, Moucha CS. Antibacterial surface treatment for orthopaedic implants. *Int J Mol Sci.* 2014;15(8):13849-80.
40. Chernousova S, Epple M. Silver as antibacterial agent: ion, nanoparticle, and metal. *Angew Chem Int Ed Engl.* 2013;52:1636–53.
41. Mijnenonckx K, Leys N, Mahillon J, Silver S, van Houdt R. Antimicrobial silver: uses, toxicity and potential for resistance. *Biometals.* 2013;26:609–21.
42. Noda I, Miyaji F, Ando Y, Miyamoto H, Shimazaki T, Yonekura Y, et al. Development of novel thermal sprayed antibacterial coating and evaluation of release properties of silver ions. *J Biomed Mater Res B Appl Biomater.* 2009;89:456–65.
43. Panacek A, Kolar M, Vecerova R, Pucek R, Soukupova J, Krystof V, et al. Antifungal activity of silver nanoparticles against Candida spp. *Biomaterials.* 2009;30:6333–40.
44. Wafa H, Grimer RJ, Reddy K, Jeys L, Abudu A, Carter SR, et al. Retrospective evaluation of the incidence of early periprosthetic infection with silver-treated endoprostheses in high-risk patients: case-control study. *Bone Joint J.* 2015;97:252–7.
45. Harges J, von Eiff C, Streitbuenger A, Balke M, Budny T, Henrichs MP, et al. Reduction of periprosthetic infection with silver-coated megaprotheses in patients with bone sarcoma. *J Surg Oncol.* 2010;101(5):389–95
46. Tsuchiya H, Shirai T, Nishida H, Murakami H, Kabata T, Yamamoto N, et al. Innovative antimicrobial coating of titanium implants with iodine. *J Orthop Sci.* 2012;17(5):595–604.
47. Guillaume O, Garric X, Lavigne JP, Van Den Berghe H, Coudane J. Multilayer, degradable coating as a carrier for the sustained release of antibiotics: preparation and antimicrobial efficacy in vitro. *J Control Release.* 2012;162:492–501.
48. Tang Y, Zhao Y, Wang H, Gao Y, Liu X, Wang X, et al. Layer-by-layer assembly of antibacterial coating on interbonded 3D fibrous scaffolds and its cytocompatibility assessment. *J Biomed Mater Res A.* 2012;100:2071–8.
49. Neut D, Dijkstra RJ, Thompson JI, Kavanagh C, van der Mei HC, Busscher HJ. A biodegradable gentamicin-hydroxyapatite-coating for infection prophylaxis in cementless hip prostheses. *Eur Cell Mater.* 2015 Jan 2;29:42-55.
50. Osmon DR, Berbari EF, Berendt AR, Lew D, Zimmerli W, Steckelberg JM, Rao N, Hanssen A, Wilson WR; Infectious Diseases Society of America. Executive summary: diagnosis and management of prosthetic joint infection: clinical practice guidelines by the Infectious Diseases Society of America. *Clin Infect Dis.* 2013 Jan;56(1):1-10.
51. Bratzler DW, Dellinger EP, Olsen KM, et al. Clinical practice guidelines for antimicrobial prophylaxis in surgery. *Am J Health-Syst Pharm.* 2013; 70:195–283.